CIHRT Exhibit P-2623 Page 1

VOLUME TWO

Ackerman's

SURGICAL PATHOLOGY

JUAN ROSAI, M.D.

Chairman, Department of Pathology
James Ewing Alumni Chair in Pathology
Memorial Sloan-Kettering Cancer Center;
Professor of Pathology
Cornell University Medical College
New York, New York

EIGHTH EDITION
with 3295 *illustrations,* 898 *in color*

Mosby

St. Louis Baltimore Boston Carlsbad Chicago Naples New York Philadelphia Portland
London Madrid Mexico City Singapore Sydney Tokyo Toronto Wiesbaden

Mosby
Dedicated to Publishing Excellence

A Times Mirror Company

Publisher: Anne S. Patterson
Senior Managing Editor: Lynne Gery
Project Manager: Carol Sullivan Weis
Senior Production Editor: Pat Joiner
Design Manager: Sheilah Barrett
Manufacturing Manager: Theresa Fuchs

EIGHTH EDITION (two volumes)
Copyright © 1996 by Mosby–Year Book, Inc.

Previous editions copyrighted 1953, 1959, 1964, 1968, 1974, 1981, 1989

All rights reserved. No part of this publication may be reproduced, stored in a retrieval system, or transmitted, in any form or by any means, electronic, mechanical, photocopying, recording, or otherwise, without prior written permission from the publisher.

Permission to photocopy or reproduce solely for internal or personal use is permitted for libraries or other users registered with the Copyright Clearance Center, provided that the base fee of $4.00 per chapter plus $.10 per page is paid directly to the Copyright Clearance Center, 27 Congress Street, Salem, MA 01970. This consent does not extend to other kinds of copying, such as copying for general distribution, for advertising or promotional purposes, for creating new collected works, or for resale.

Printed in the United States of America
Composition by Accu-color/Beaumont Book Division, Inc.
Printing/binding by Von Hoffmann Press, Inc.

Mosby–Year Book, Inc.
11830 Westline Industrial Drive
St. Louis, Missouri 63146

Library of Congress Cataloging in Publication Data
Rosai, Juan. 1940–
Ackerman's surgical pathology.—8th ed./Juan Rosai.
p. cm.
7th ed. cataloged under Ackerman.
Includes bibliographical references and index.
ISBN 0-8016-7004-7
1. Pathology, Surgical. I. Ackerman, Lauren Vedder, 1905–.
Surgical pathology. II. Title
[DNLM: 1. Pathology, Surgical. WO 142 R788a 1995]
RD57.A2 1995
617' .07—dc20
DNLM/DLC
for Library of Congress 95-36167
CIP

95 96 97 98 99 / 9 8 7 6 5 4 3 2 1

CIHRT Exhibit P-2623 Page 3

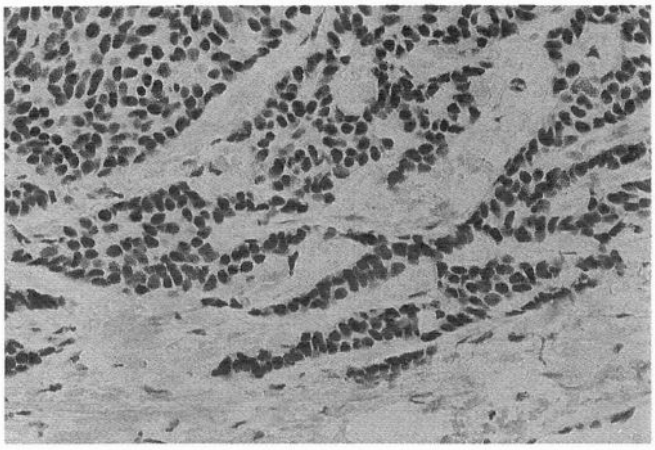

Fig. 20-70 Immunocytochemical stain for estrogen receptors in invasive breast carcinoma. The strong nuclear positivity in tumor cells is shown against a negative cytoplasmic and stromal background.

are probably more closely related to ductal carcinoma of either invasive[588] or in situ type.[587]

The intracellular mucin accumulation resulting in the signet ring appearance is probably the result of a blockage in secretion resulting from deletion of one or more of the enzymes needed for this extremely complex process. Ultrastructurally it is manifested in its more extreme form by a large membrane-bound vacuole of varying but usually low electron density.[593] This is a different process from that of intracellular lumen formation, which is characterized ultrastructurally by a microvillus-coated cavity and which appears as a bull's-eye on light microscopic examination.

Other types. Some authors restrict their diagnosis of ILC to tumors having the features described for the classic type and for some of the signet ring carcinomas. Others have expanded considerably the concept and include in this category tumors that traditionally have been placed into the IDC category.[594,597,599] Cases having closely aggregated cells, solid pattern, trabecular pattern, loose alveolar pattern, and spindle-cell chains have been accepted as ILC, *as long as the relatively bland and homogeneous cytologic appearance was maintained.* Perhaps the most distinctive of these forms is the alveolar variant, in which the tumor cells are arranged in sharply outlined groups separated by fibrous tissue sometimes containing osteoclast-like giant cells.[600,601] Yet another variation is represented by *tubulolobular carcinoma,*[598] in which typical areas of ILC merge with small tubules with a minute or undetectable lumen ("closed" or "almost closed" tubules). A converse approach has been taken more recently, and that consists of including tumors with pleomorphic nuclear features into the ILC *as long as the infiltrating pattern* of classic ILC is maintained. Such tumors have been designated as the *pleomorphic variant* of ILC[602]; the further suggestion has been made that this tumor shows apocrine differentiation.[596]

The cytologic and/or architectural similarities between these various forms and classic ILC are undeniable. The problem, however, is that the more the concept of ILC is widened and to some extent diluted, the less distinct the entity becomes and the less significant (or at least the less uniform) its clinical connotations are.[595]

Mixed ductal and lobular carcinoma

Biphasic carcinomas composed in part of a component with definite features of invasive ductal carcinoma and in part of a component with definite features of invasive lobular carcinoma do occur, but they are very rare. These tumors, of course, should be distinguished from the cases in which two separate neoplasms of different microscopic appearances are present in the same breast.

Undetermined (unclassified) carcinoma

This category includes all cases of invasive carcinoma in which features of ductal or lobular type are not definite enough to place it into either category. Azzopardi[603] places 3% to 4% of the invasive breast carcinomas in this category.

HORMONE RECEPTORS

A very important development in the evaluation of breast carcinoma is the realization that the presence of hormone receptors in the tumor tissue correlates well with response to hormone therapy and chemotherapy.[613] The hormone (estrogen and progesterone) receptors can be measured by the standard dextran-coated charcoal and sucrose gradient assays or by immunohistochemical techniques using monoclonal antibodies directed against the receptor molecule (Fig. 20-70). Fresh tissue is needed for the biochemical methods, whereas sensitive and reproducible techniques are now available for the immunohistochemical detection of the receptor in formalin-fixed, paraffin-embedded material.* Correlation between the biochemical and the immunohistochemical methods is very good.[604] The latter is preferable when the sample is very small and when the proportion of tumor tissue as opposed to fibrous stroma is reduced. Actually, most evidence suggests that the immunohistochemical assay will become the gold standard if it has not already.[606,606a] The method can be semiquantitated by computer-assisted image analysis.[605,610] Estrogen receptors can also be detected by the in situ hybridization technique, which is actually a more sensitive method than either immunohistochemistry or the biochemical assay.[612]

Not much correlation exists between the cytoarchitectural type of breast carcinoma and presence of hormone receptor protein; specifically, no statistically significant difference has been found between ductal-type and lobular-type tumors. However, most series have shown that most medullary carcinomas and intraductal carcinomas of the comedocarcinoma type are negative,[614,621,624,626] whereas mucinous carcinomas have the highest rates of positivity.[617] In DCIS, a predominance of large cells is the best morphologic predictor of estrogen receptor–negative status.[608]

Generally, estrogen receptor concentrations are lower in tumors of premenopausal women than in those of postmenopausal women.[624] Fisher et al.[611] found the presence

*References 615, 616, 618, 619, 620, 622, 623, 625.

CIHRT Exhibit P-2623 Page 4

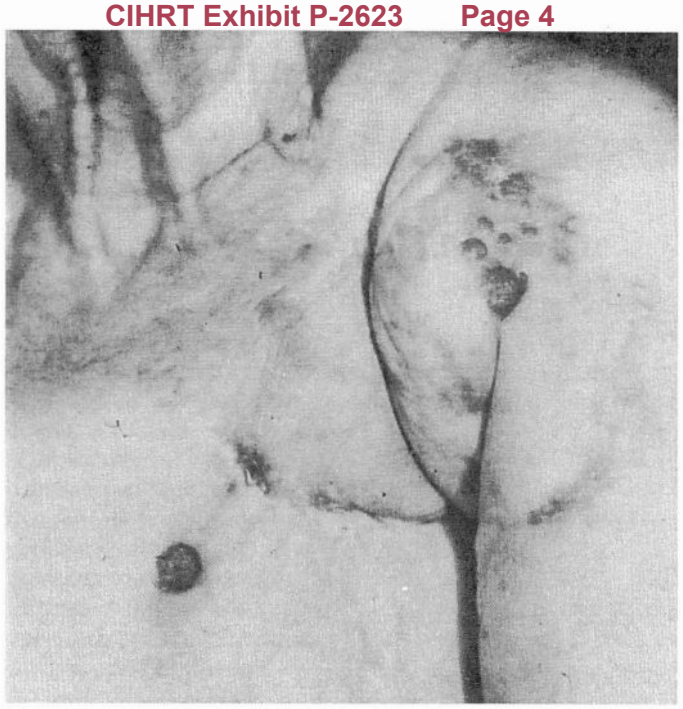

Fig. 20-71 Patient with local recurrence of carcinoma 27 years after original operation.

of estrogen receptors to be significantly associated with high nuclear and low histologic grades, absence of tumor necrosis, presence of marked tumor elastosis, and older patients' age groups. Hormone receptor positivity also correlates with bcl-2 immunoreactivity[607] and absence of p53 mutations,[609] and it correlates inversely with the presence of epidermal growth factor receptors.[626a]

SPREAD AND METASTASES

Breast carcinoma spreads by direct invasion, by the lymphatic route, and by the blood vessel route.[652] Some of these metastases are already present at the time of diagnosis, and others become manifest clinically months, years, or decades after the initial therapy[628] (Fig. 20-71).

Local invasion can occur in the breast parenchyma itself, nipple, skin, fascia, pectoralis muscle, or other structures of the chest wall. The frequency of microscopic invasion in the breast outside the gross confines was evaluated by Rosen et al.[653] by performing a "local excision" with a 2-cm gross margin in specimens of radical mastectomy and studying microscopically the remainder of the breast. Of eighteen mastectomies for carcinoma measuring less than 1 cm, residual invasive carcinoma was found in 11% and residual in situ carcinoma in an additional 22%. The importance of a proper pathologic evaluation of local invasion in breast carcinoma is now greater because of the increasing number of conservative surgical procedures being performed.[631]

A somewhat related problem is that of microscopic involvement of the nipple by breast carcinoma, since this structure would obviously be left in the patient if a local excision of the lump were carried out. Nipple invasion has been found in 23% to 31% of all invasive carcinomas; the large majority are seen in tumors located less than 2.5 cm from the nipple.[641,648,655]

Local recurrence following mastectomy appears as superficial nodules in or near the surgical scar or as subcutaneous parasternal nodules. Their malignant nature should always be documented by biopsy because the condition can be closely simulated by foreign body granulomas and infectious processes. Although women with local recurrences have an increased risk of distant metastases,[639] these seem to represent partially independent events that occur at different times.[654a]

Tumor recurrence following local excision often develops in the same segment, a fact that has led some authors to recommend a primary excision technique that removes en bloc the tumor mass and the associated duct system.[640b]

The most common site of lymph node involvement is the axilla, followed by the supraclavicular and internal mammary region. Axillary node metastases are present in 40% to 50% of the cases and are divided into levels according to their topographic relation with the insertion of the pectoralis minor muscle: low or proximal, medium, and high or distal. When extensive they are clinically detectable, but the margin of error with clinical palpation is high. Careful dissection of the submitted nodes by the pathologist is of importance. The yield of nodes will increase if they are searched for after the axilla is cleared with an organic solvent, but this seems hardly worth the trouble and expense. The yield of